

Chapter VI

Dental Origins of Stress

In general, the thesis of the present work may be expressed as follows: Malocclusion of various types (including excessive free-way space) results in imbalance of the neuromuscular systems of the big three – breathing, swallowing, and chewing since they are interrelated and the function of each depends upon the others. Any imbalance therefore inhibits normal synergistic action of all muscles controlling the mandible. Confusion arises in the relay of neural impulses to and from the brain. These confused impulses result in erratic and unnatural contractions of the musculature. This interruption of normal muscle function leads to muscle spasms, improper muscle tonus, and, in time, degeneration of muscle tissue. As a matter of routine, disorder of the temporomandibular joint coexists with imbalance of the masticatory muscles. The TMJ disorder is not the cause; it is a symptom area that must be treated as part of a complex of somatic and psychic alterations.

This malfunction of the musculature is a cause of constant distress within the body, for it is responsible for alterations in the skeletal, neural, and vascular structures causing physiopathologic changes throughout the body. Distress will persist until physiologic rest position of the mandible is established, physiologic inter-occlusal space and proper occlusal stop are provided, and proper synergistic muscle function restored. Alleviation of this distress is the responsibility of the dental physician.

I. The Musculature Controlling the Mandible

An understanding of the participation of the 16 sets of musculature in the precise and sensitive movements of the mandible is indispensable. It is well understood that the temporomandibular joint and its movements differ greatly from any other joint in the body, and it is also well understood that this joint cannot serve as a stress-bearer without complications arising therefrom. But the fact that the healthy temporomandibular joint is one that is functioning in a freely moving, suspended relationship is not well enough understood.

Thompson states that normal movement of the mandible from rest position to occlusal position is almost purely a hinge movement, with the axis located in the vicinity of the condyle or lower portion of the joint.¹ There may be a slight condylar movement as this axis is slightly below the center of the condyle, and this minimal movement should be considered normal. When rest position is exceeded, the condyle moves downward and forward in a straight line.

Sinclair² observed and demonstrated, both in open surgery and in fluoroscopic series, the floating action of the mandible during mastication. The condylar head did not glide on body surfaces that were cushioned away from the surfaces of the glenoid fossa and the articular eminence.

In open surgery, under local anesthesia where the third division of the trigeminal nerve could not be affected, the functional movements of the head of the condyle were constantly observed in all patients to float freely, and even down and out of sight during movements of the mandible. Boucher³ states that *this floating action of the mandible can be explained by the neuromuscular system that controls the mandible.*

Cinefluorography has been used often to study the movements of the mandible and especially of the temporomandibular joint. In a study by Boucher, Scotter, and Charlebois⁴ of the protrusive movements of thirty subjects divided into angles three classifications showed no significant difference, but the condyle in all three classifications followed a straight line instead of intimately following the articular eminence in a typical "S" curve. The mandible did float freely and the condyle was not following the skeletal contour of the opposing joint structures in a stress-bearing manner.

Guzay,⁵ in his well documented Quadrant Theorem, demonstrates that the temporomandibular joints are secondary counter balancing points. The muscles above and below the mandible control functions and the center of rotation is between the first and second cervical vertebra. So the ideal plane of occlusion is flat and any curve of spee is pathological. The deeper the curve of spee the greater the problem. This philosophy has been utilized by the Academy for Functional Prosthodontics so successfully for many years. All set-ups for dentures are based on this philosophy as well as all treatment of dentulous TMJ dysfunction cases with an extremely high success rate.

That the temporomandibular joints cannot properly serve as the centers for mandibular rotational function is well documented by measurements and it is high time that pre-dental prerequisites include a basic course in physics so that our profession is able to fully comprehend the dynamics of occlusal function.

The importance of the proper understanding of these concepts when performing dental care comes into focus when one reviews the many cephalometric laminagraphic studies by Ricketts, who feels that joint pathology, in the majority of cases, is directly or indirectly due to malocclusion. He states that:

Clinical problems can result from alterations of less than one millimeter in the relation of condyle to fossa. The muscles of mastication possess a high innervation ratio (nerve to muscle fibers). The mandible is concerned with a highly proprioceptive sense of chewing. But of equal importance is the concern with the movement of the tongue during deglutation and speech. The temporomandibular joint therefore, is responsive to movements of

the tongue, and conditions of the pharynx for the wide range of functions it is called upon to serve. It is further concerned with the postural relation of the head, as the mandible is suspended and held in place by the muscles of mastication, and the suprahyoid and infrahyoid complex.⁶

Any muscle can, when activated, work in one of three distinct roles: it may, isotonicly, contract and shorten to act as a *mover*; it may, isotonicly, contract and lengthen to act as a *balancer*; and it may, isometrically, contract but neither shorten nor lengthen, to maintain its dimensions and act as a *holder*. In all these functional, purposeful movements, groups of muscles cooperate. Basically, the coordination of muscles of any group is achieved mainly by feedback to the brain from the proprioceptive nerve endings found in muscles, tendons, ligaments, and articular capsules. So in the group of mandibular muscles, the proprioceptors of the periodontal ligaments act as an especially precise guiding principle.

Thus, normal synergistic function of the mandibular musculature depends upon the transmission to the brain of the correct proprioceptive neural impulses. When the brain receives the correct neural stimuli, it is able to accomplish three functions:

1. It can position the mandible in the *physiologic rest position*.
2. It can move the mandible into the *normal occlusal position*.
3. It can guide all the *movements* of the mandible (without improper contractions of the musculature).

Rest position and occlusal position constitute the two fundamental positions of the mandible. True rest position may be defined as the mandibular position in which the mandible can be held in a stable position with all the muscles of the head and neck assuming their physiologic length.⁷ Rest position is constant.⁸ It is established before the teeth have erupted, and commands a high degree of stability even after the teeth have been lost.⁹ All functional movements of the mandible begin and end in the rest position,^{10 11} which is entirely dependent upon the musculature.^{12 14} The mandible is maintained in a resting position most of the time.¹⁵

There are variables in the rest position.¹⁶ They are related to variations in the tonicity of the musculature such as (1) hypotonicity, as seen in fatigue, disease, and generally diminished muscular tone, and (2) hypertonicity, which in the extreme is trismus. These may completely supplant or alter the normal rest position.¹⁷

While six pairs of muscles “control” chewing at least forty pairs of muscles and ligaments will be affected by the rest position of the mandible. These muscles and ligaments in the head and neck never rest but remain in a state of tonus, i.e., in a state of partial contraction of some of their fibers. This tonus is necessary for proper stability of skeletal structures and for synergistic function. These muscles and ligaments have

a given length which is their physiologic resting length. The tonus necessary to support the skeletal structures involved must coincide with the physiologic resting length if distress is to be avoided. If correct rest position of the mandible exists, then the skeletal supporting tonus and physiologic resting length of the musculature so coincide. However, if there is malocclusion, then the neuromuscular physiology is disturbed and the patient will possess a pathologic and unstable rest position, and the muscles and ligaments involved will not be maintained at their physiologic resting length. They will be in a state of improper tonus, and thus constitute a constant source of distress. We must recognize that the skeletal bones are held together and positioned by muscles and ligaments. When one area is out of balance the remaining musculature and skeleton automatically assumes a balancing distortion.

A. INTER-OCCLUSAL SPACE. Another source of stress is excessive interocclusal space, which disturbs muscle function in chewing and swallowing. When there is overclosure, some muscles must overshorten and reciprocal muscles must overlengthen. This initiates distress in chewing and swallowing. Muscle tonus gradually diminishes. The forty pairs of ligaments and muscles attached to the mandible are affected, as well as the related skeletal and soft tissue structures. Even the timing of muscle contractions in the closure of the air passage, when swallowing food, is no longer perfectly synchronized, and this frequently results in choking problems when eating.

Occlusal relationships also undergo constant changes through wear, faulty restorations, drifting and migrating of teeth, etc. When these changes result in malocclusion, it disturbs the delicate neuromuscular relationships. Thus, an unstable, faltering, indefinite and tense rest position can result from improper occlusal position.

We have established that improper contraction of the mandibular muscles confuse the proprioceptive impulses relayed to the brain, and that prematurities and eccentricities in dental contact will also confuse the proprioceptive stimuli reaching the brain from the periodontal tissues. These confused impulses prevent rhythmic and well coordinated mandibular movements and prevent the mandible from returning to its relaxed and proper rest position from the defective occlusal position.

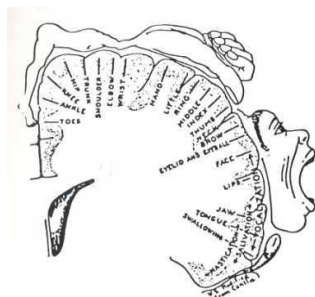


Fig. 12 Motor homunculus illustrating motor representation in area 4 (anterior central gyrus). (After Penfield and Rasmussen, Cerebral Cortex of Man, The Macmillan Co.)

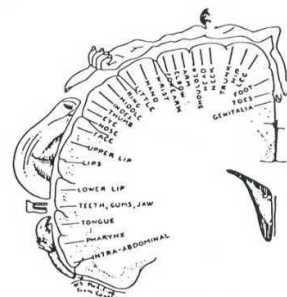


Fig. 13 Sensory homunculus showing sensory representation in the sensory cortex. (After Penfield and Rasmussen, Cerebral Cortex of Man, The Macmillan Co.)

Since approximately half of the brain is devoted to the oro-facial area, when confused stimuli is accepted as fact by the master-computer-brain, it will in turn be sending out faulty information to the body and this will affect all systems of the entire body. With half truths the brain is reporting that all is well when in fact all is very wrong. Gradually diseases appear throughout many systems of the body and when the malocclusion is eliminated we see the reversal of these “chronic” health problems.

Normal occlusion may therefore be defined as

...that mandibulomaxillary relationship supported by natural or artificial dentition which permits all the structures directly or indirectly dependent on that relationship to function in a state of equilibrium.¹⁸

When correct occlusal position and physiologic rest position have been established, proper inter-occlusal space will have been achieved. This interocclusal space is the distance between these two basic positions of the mandible.

Neither an excessive nor insufficient interocclusal space will be well tolerated. Degeneration of muscle tissue and loss of function must result. This can be readily observed clinically by checking out the different pairs of muscles during functional movements. By placing the pads of the educated finger tips against the working muscles, one can detect the weakness or complete lack of contraction. Later, this can be compared with the more vigorous contractions of healthy functioning muscles after definitive dental treatment has restored normal physiological function for a period of time sufficient to allow these muscles to regenerate and reacquire proper tonus. Only under a stress-free condition will this regeneration of muscle tissue occur and good muscle tonus return.

The most important element in treatment, therefore, becomes the establishment of physiologic rest position. To achieve this basic position, a physiologically functional occlusal position must be secured, with an acceptable inter-occlusal space. The experience of the author shows that these conditions can be best achieved through a definite treatment program. When the interocclusal space is considerable, one can use an acrylic template (splint) that must be periodically adjusted to accommodate the changing mandibular posture as the muscles heal and regain proper tonus. If the interocclusal space is almost normal, occlusal fillings overlaying the molar teeth can be employed using the same treatment approach. Treatment dentures can be constructed for the edentulous. The treatment procedure and regeneration of muscle tonus takes several months in some cases.

When physiologic rest position, normal occlusion, and proper interocclusal space have been provided, the temporomandibular joint problem is thereby eliminated, because the abnormal movements of the joint that precipitated this condition no longer occur. A long held but mistaken belief that the TM joints are the primary centers of mandibular motion has been proven to be wrong by the discoveries of the Denture Research Group of Chicago. Guzey's Quadrant Theorem through actual

coordinated measurements proves that the center of mandibular rotation is dictated by the totality of head and neck muscular balance and this center is between the first and second cervical vertebrae. The TM joints are instant (balancing) centers in mandibular function. When the joints become *stress bearing areas* as is seen most often in Class II malocclusions, the curve of Spee deepens and the TMJ movement is excessively loose. Class I and III malocclusions create “less” joint pathology.

B. MUSCLE SPASM. Muscle spasm is a reversible state of shortening which is no longer under voluntary control. It is usually associated with neutral reflex action. Muscle spasm results from a disturbance of the stomatognathic structures and causes dysfunction, tenderness, and pain within the temporomandibular joint. A concomitant characteristic is almost always restricted mandibular movement. Owing to protective splinting, muscles that are affected can cause other muscles or other sections in the same muscle to go into spasm. In this manner, the effect and the areas of the spasm are greatly increased. In the acute stage, muscle spasm appears to be a neurophysiologic disorder, but with the passage of time, the spasm becomes chronic, and the tissues undergo organic change. The cycle – muscle spasm, pain, spasm – can be initiated by pathologic occlusion which creates neuromuscular dysfunction. The mandible then assumes an unphysiologic convenience relationship with the maxilla and the coordination of the neuromuscular system is thrown out of balance. The condyles, the rami, and the body of the mandible are now in an unphysiologic position. The muscles, the tendons, and the ligaments attached to these are also in a convenience relationship. However, the normal reflex control of the muscles is constantly attempting to return the mandible to proper physiologic relation. This continuous stimulation causes the muscles to remain in a state of sustained contraction without movement. The effect of this uncoordinated neuromuscular activity is chronic muscle spasm.

The spastic hyperactivity of the mandibular musculature may initiate degenerative changes in the temporomandibular joint merely by increasing and sustaining abnormal pressure on the fibrous tissues of the articulation. Clinical and pathologic observations, however, indicate that in the majority of joint diseases, a more complicated and more severely injurious mechanism is active.

Two factors in regard to the articular disc must be remembered: the attachment of muscle fibers on its anterior rim, and the loose attachment of its posterior edge to the capsule. If the mandible falls into spastic contractions, the unilateral muscle attachment eventually will cause a displacement of the disc with relation to the condyle. As the irritated muscles fight against each other, the disc may be held in place while the mandible is displaced posteriorly, or the mandible may be stabilized while the disc is displaced anteriorly, or, more probably, a combination of these possibilities may result.¹⁹

Emotionally tense people and those with a history of general musculoskeletal spasm are predisposed to spasm of the muscles of the stomatognathic system. Other generally accepted predisposing causes are

nutritional deficiencies, syndromes of the menopause, male climacteric, and hypometabolism. The symptomatology of muscle tenderness, pain, and spasm varies with the class and the severity of the pathologic occlusion.

C. REFERRED SYMPTOMS OF HEAD AND NECK. Lewis²⁰ has demonstrated that muscular dysfunction can give rise to referred pain. Whatmore and Kohli show that dysfunction causes disease processes to develop throughout the bodily systems. Head and neck pains associated with disturbance of musculature and temporomandibular joint dysfunction are generally considered to be referred. The perceived pain is caused by nerve stimulation rather than nerve impingement. These pains are dull, constant, and unrelenting in nature, and are aggravated by mandibular movement. The pain is not limited to the distribution of the trigeminal nerve; other nerves may be involved. The pain symptoms are reported in various groups and combinations, depending on the patient. Patients with dysfunction of mandibular muscles may complain of pain in any of the following areas: frontal, temporal, vertex, occipital, parietal, buccal, supraorbital, infraorbital, zygomatic, nasal, angle of the mandible, mental, preauricular, ear, postauricular, and cervical. Other areas of pain are: the soft and the hard palates, the throat, the maxillary and the mandibular teeth, the submaxillary gland region and the maxillary sinus.

Neural manifestations in the ear, such as tinnitus, buzzing and whooshing noises, stuffiness and blockage, may have their source in vascular dystrophy resultant upon muscular malfunction, as demonstrated by Thonner.²¹ His anatomic investigation demonstrates a hitherto unreported vascular connection from the internal maxillary artery to the inner ear.

Freese and Scheman provide the following summary of referred pain:

A myofascial trigger area is a small, circumscribed, very hypersensitive area in myofascial tissues from which impulses arise to bombard the central nervous system and produce referred pain. This area exhibits deep hyperalgesia, fasciculation, and referred pain. It should be emphasized that it is a physical sign, not a symptom, and the patient is usually unaware of it.²²

The myofascial trigger-mechanism has implications that extend to all areas of the body. As Travell has pointed out, myofascial trigger areas have been found in the skeletal muscles of patients with disorders as different as tension headache, acute painful torticollis, calcific bursitis and other painful shoulder syndromes, myocardial infarction and effort angina, musculoskeletal types of chest and breast pain, low back pain and sciatica, osteoarthritis of the hip, intermittent claudication, and traumatic and postoperative pain syndromes, including those of the abdominal musculature. A syndrome of postural vertigo and headache is also due to a myofascial trigger mechanism. Travell and Bigelow have shown that the patterns of hysteria are associated with myofascial trigger areas. However,

a strong warning is in order here: clearing up the symptoms of patterns of hysteria by blocking the myofascial trigger mechanism can lead to disintegration of the ego. Travell and Bigelow insist that hysteria must be treated only by psychotherapy.²³

D. SUMMARY. Disturbance of the smooth, synergistic function of the muscles of the mandible causes severe imbalance, degeneration of tonus, and in time, actual breakdown of tissue. It also disrupts the normal proprioceptive neural pathways between the periodontal tissue, the muscles of mastication, and the brain. A cycle of pain-spasm-pain begins. Through the myofascial trigger mechanism, referred pain may occur in many areas of the head and neck, as well as in more distant parts of the body. All these factors are sources of stress in the patients, capable of initiating the General Adaptation Syndrome. If they persist, or if they are compounded by a further stress factor, they can produce diseases of adaptation anywhere in the body.

II. Disturbed Skeletal Relationships and Postural Symptoms

Thus far, our concern has been with the neuromuscular relationships which are disrupted in the malocclusion patient. A hint has appeared from time to time that this improper function of the muscles also causes disturbed relationships and malfunction of related skeletal and vascular structures. It is necessary now to turn our attention to those.

There can be little doubt that the most important concept that has emerged from dental research is that of the Dental Distress Syndrome (DDS), a syndrome routinely affecting the respiratory system^{40 44} and spinal posture,^{45 47} and causing physiopathological alterations^{48 49} throughout the total biologic unit.⁴⁷ This abnormal stress of dental origin not only activates Selye's General Adaptation Syndrome (GAS) but progressively stimulates it until the dentist intervenes. Conversely, widespread normalization is observed throughout the total biologic unit, when these destructive forces are altered to achieve a physiologically functioning masticatory system.^{42,47} (See Table.)

Activists In This Field Of Care

Chronically ill patients afflicted by DDS are being treated by many specialists and professional teams including the members of the American Academy of Stress and Chronic Disease; The American Academy of Physiologic Dentistry; The American Academy of Craniomandibular Orthopedics; The American Academy for Functional Prosthodontics; and select members of the International Academy of Preventive Medicine, of the American Equilibration Society, of the Doctor's Dental Service of Chicago, and of the American Association for the Advancement of Tension Control.

The internationally known physician Alexander B. Leeds⁴⁰ spent the final decade of his life treating DDS patients and researching with a dental colleague, Willie May. Dr. Leeds never relinquished his role as a

student; he devoted four hours daily to reading and study throughout all of his years of medical practice.

Dr. Leeds pioneered in orthomolecular medicine and bio-medics in the 1940s; introduced the Menninger brothers to psychiatric medicine; was consultant to the American Armed Forces for World War II and to the Atomic Energy Commission; was with President Roosevelt when he had his 27th heart attack; was Eisenhower's personal physician; was flown to Russia to care for Stalin; was flown to the European Theatre when Patton had his breakdown; screened all personnel for the Atomic Energy Commission; etc.

When Dr. Leeds came to Dr. May for dental care he was so debilitated that he had to pause for breath to complete a statement. Treatment was very successful and he was able to double his own patient load within six weeks. From that time on Leeds and May jointly treated more than 1,200 DDS patients, although in the beginning they did not recognize they were primarily reducing stress. Dr. Leeds ascribed to this treatment the extension of his medical practice by several years.

An early pronouncement was that this treatment could be expected to add ten years to a person's life if it was begun near middle age. After observing 1,200 patients Leeds' conclusion was, "This is the greatest aid in the treatment of chronic symptoms that I have come across in over 50 years of medical practice."⁴⁰ Still later he said, "When completely developed this treatment will be capable of revising every diagnosis, treatment procedure and prognosis in the medical world." His final prediction was, "This may well be a focus point around which all modalities in the medical world can begin to agree."⁴⁰

Henry Uhlemeyer, an otolaryngologist, long an advocate of correcting the dental malocclusion to reduce stress, gets his greatest enjoyment from enabling bed-ridden and wheelchair geriatric patients to walk and be self-sufficient by eliminating the DDS.⁵⁰

John Diamond, President of the International Academy of Preventive Medicine, after receiving several research awards in the field of psychiatry, says that he gets consistently better results now that he concentrates on the reduction of stress, especially the DDS problem. He no longer uses the conventional psychiatric treatment procedures.⁵¹

The schools of osteopathy, chiropractic, physical therapy and Alexandering have been especially quick to recognize the role of DDS in the prevention of disease and in the restoration to health, for the restoration of proper posture and function is essential to their fields.

Dental Distress

The fact that excessive dental stress not only activates the GAS but progressively stimulates it until the physiologic dentist intervenes⁴²⁻⁴⁷ makes dental stress different from most stressors that attack the host, for the body usually is able to eliminate or avoid other stressors (e.g., infection, poison, over-stimulation, duress, etc.).

The DDS results from stressful malocclusion of the teeth and imbalance of the powerful masticatory complex of muscles, with a reciprocal imbalance of the infra-mandibular complex of neck and shoulder musculature. This disturbs the postural relationships of the structures of the head, neck, shoulders, spine and pelvis,⁴⁷ creating a powerful and dominant condition that constantly produces distress until a physiologically balanced maxillomandibular relationship is achieved.

Postural Systems

The jaws, the teeth and their supporting tissues, the muscles of mastication, and the temporomandibular joint are all components of the masticatory system. However, these are not the only important structures. Chewing, swallowing, respiration and speech *must* work in harmonious balance or we have complications.

The entire musculature of the head, neck and shoulder girdle are also affected. In the cervical region, the hyoid bone forms another integral part of the dental mechanism. The hyoid bone resembles the U-shaped mandible on a smaller scale, and together with the mandible and the anterior part of the shoulder girdle, forms a series of bow-shaped structures with interconnecting musculature. This musculature works in conjunction with the musculature above the mandible, and together the two create a suspensory apparatus that controls mandibular function, the balance of the jaws, head, and shoulders and the relativity of all attendant structures (Figs. 1-11).^{41 47}

Besides the hyoid mechanism, the neck contains the trachea, larynx, and thyroid and cricoid cartilages with their accompanying musculature. Taken together, these structures provide a link between the head and chest system.^{52 53} Therefore, if there is maladjustment of any of these structures because of incorrect positioning of the mandible, reactions will be visible in the interruption of proper function in the swallowing, speech, hearing, and breathing processes.^{41 47 52 54}

These postural changes create additional problems because of the resultant displacement of organs, distortion of the lumina of vessels, and pressure on nerves, to mention a few obvious consequences.⁵⁴ Other observable adaptations are alterations of the blood pressure, pulse rate, endocrine balance, body chemistry, blood count, cell quality and form, thyroid activity, skin, muscle strength, hearing acuity, etc.^{42 47}

Why The Dental Area Is Important

The importance of all associated masticatory muscles functioning optimally can be better understood when we consider the following:

1. Almost half of the motor and sensory function of the brain is devoted to the “dental area” (Figs. 12-13).

2. The computerized brain is programmed by feedback whether it be factual or errant.⁵⁵
3. The facial musculature instantaneously registers fear, anger, love, hate, joy, surprise and all emotions.
4. Kinesiology has clearly demonstrated that each tooth is associated with a muscle and an organ in energy patterning of the body.^{56 58}

Related Findings

Nobel Laureate Tinbergen refers to Alexander's normalization of body posture by manipulation of the body musculature.⁵⁹ By removing this stress, a variety of somatic and psychic illnesses are thereby eliminated. Barlow⁶⁰ describes the successes of Alexander's pupils as the "rag bag" of rheumatism, arthritis, respiratory disorders, asthma, high blood pressure, circulation defects, heart conditions, gastrointestinal disorders, gynecological conditions, sexual failures, migraine, depression, depth of sleep, overall cheerfulness, mental alertness, resilience against outside pressures, refined manual skills and a wide spectrum of diseases, both somatic and psychic. These normalizations observed through Alexandering to correct body posture are also observed regularly when posture and function are normalized by elimination of the DDS.^{42 47}

John Dewey⁶¹ stresses the importance of Alexander's therapy, as does Huxley⁶² and, more convincingly, such renowned scientists as Coghill,⁶³ Dart⁶⁴ and the great neurophysiologist Sherrington.

Recent neurophysiological discoveries make the Alexander therapy results and the claims of physiologic dentistry more plausible, such as the key concept of reafference,⁵⁵ the discovery of von Holst and Mittlestaedt. It appears that at certain levels of integration from single muscle units to complex muscle behaviors, the correct performing of many movements is continuously monitored by the computerized brain by comparing feedback reports that tell the brain when to cease an order. Only when the feedback and the feedback mechanism match does the brain cease sending out commands for corrective action. Mittlestaedt and von Holst believe that this complex mechanism can vary from moment to moment when the initial state of the subject – the "target-value" or Sallwert of the expected feedback – changes with the motor commands that the brain gives.

Additional clarification of the effects of muscle-function disorders can be found in the research of Whatmore and Kohli.^{48 49} The physiopathological disorders created by mandibular and temporomandibular joint (TMG) dysfunction are easily understood when we consider how stress and physiopathological input are handled by the biologic unit and what effect they have on the soma and psyche.^{42 47}

Scientists are still searching for the primary cause of bad posture, and phenotypic rather than genetic causality is suspected. Now, a

growing number of medical and dental practitioners and researchers are convinced that dentistry had this answer in the DDS.

Memory Patterns

A lifetime of misuse of the body muscles upsets the entire system so that the brain, the “great computer,” reports that all is well when in fact all is very wrong. It must be emphasized that each movement of the dental mechanism reinforces the previous patterns registered in the brain, which has approximately half of the sensory and motor areas devoted to the orofacial musculature (Figs. 12-13). If the master computer is clogged with faulty information, it automatically transmits stressful impulses to the rest of the body, requiring the expenditure of a great deal of energy in adjusting to the constant strain throughout the somatic and psychic systems.³⁵ Clearing up these pathological impulses through the correction of the distressful mandibular relationship, so that factual input is fed into the programming of the brain, offers possibilities for the elimination of many chronic and seemingly unrelated conditions.⁴⁷ Now the energies of the GAS can be expended in building up bodily tissues, healing injuries, and even retarding the aging process, since all structures are now functioning with only the stresses for which they were designed.^{47 52}

Basic Anatomy

The importance of the dental structures is easily demonstrated through a consideration of basic anatomy. The jaw and spine are gathered into one basic system by the various fascia surrounding them, so that stress or muscle spasm in these areas is reflected in tension transmitted throughout the corresponding regions and their interconnecting fascial sheath systems. This is especially true with the masticatory system and the atlas and axis vertebrae in the neck, where tension and aching often occurs, since these two areas are the most freely movable and the major weight-bearing mechanisms in the system. Research has shown how closely these structures are linked. Strain or pressure on one will produce a correlative adjustment on the part of the other. This correlative adjustment in the body's systems is evidenced in the consistency which research has demonstrated of short or reactive leg length and the laterality of axis to the maloccluded side of the temporomandibular joint.¹⁸ The intricately linked web of the muscles of the body results in reaction of neck muscles when one muscle is changed in the leg. When a neck muscle is released, the toes are affected even when one is lying down.

Comments

We swallow twice a minute when awake and once every minute during sleep. If we subject the teeth to only one pound of pressure with each act of swallowing, the dental structures would absorb approximately one ton of intermittent dental stress daily. However, the average person exerts at least 3 ½ pounds of pressure during swallowing, while the

nocturnal bruxer far exceeds this norm; so distressful malocclusion imposes many tons of intermittent dental distress that constantly upsets the balance of the body's systems, until the dentist intervenes. Such is the importance of the stimuli sent out by the chewing mechanism that one physician's study⁵⁰ concluded, "Feedback" makes *The Teeth the computerized brain's electrical control center.*

Treatment

Spinal curvature, which develops gradually over an extended period of time, begins to normalize when we adjust the "jaw relationship" and, provided we closely control the occlusal balance, we may get a reprieve from the symptoms (pain, etc.) and/or changes in the bodily systems (endocrine, neural, blood, chemistry and fluid balance).⁴⁷ But if correctional adjustments are discontinued, the body often settles into a new distressful relationship because the complete physiologically balanced structural relationship of the complex of overdeveloped (overexerting) and atrophied (unused) muscles, ligaments, bones and tissues cannot completely normalize instantaneously. It often takes months and occasionally a few years to reach optimum repositioning and a physiologically acceptable balance of structures and forces.

Thus, when we start to equilibrate teeth to "even the bite," for example, we usually have to continue equilibrating periodically over an extended period of time. Also, when we place a denture to restore lost vertical it is normally repeatedly to go "off-bite." The oral tissues may adjust to take up some of this change and/or sore spots develop. It may be necessary to reset teeth or equilibrate from time to time, and proper service often requires new dentures after a year or two with new ones constructed periodically to maintain physiological relationships. Too, full mouth reconstruction often fails or results in stressful relationships, if we do not first construct a template and over a period of time make controlled adjustments until all musculature has settled into a completely compatible physiological relationship throughout the head, neck and body.

The results of various forms of DDS are quite predictable. When a tooth is removed and a space maintainer or bridge is not constructed, a distressful mandibular relationship is created. When fillings or dentures are constructed that do not establish proper support and physiologic balance, a posture problem is created. When a deep over-bite or malocclusion is found in a patient, the body chemistry, blood and endocrine balance is affected. When tension and intermittent clamping in children has not allowed the deciduous molars to fully erupt to a physiologically balanced maxillo-mandibular relationship, the child will have repeated bouts with ear infections, tonsillitis, allergies and catch every bug and illness that happens to be around. When proper molar support is provided at the proper vertical the child is no longer susceptible; the tonsillar swelling is reduced to normal; the ear infection that did not respond to antibiotic therapy subsides without drugs. These

are typical findings. When one looks in the mouth and sees the condition and relationship of the teeth, the medical history is already obvious to the physiologic dentist. He knows what questions to ask and he knows what the answers will be. He is rarely wrong.

Conclusion

Selye's universally accepted GAS, and the discovery that dental distress activates the DDS and the GAS, should whet the appetites of medical and dental researchers, educators, specialists and general practitioners. For, in removing the condition of malocclusion and the distress factors, we are dealing with a biologic whole and not simply with teeth and dental tissues. It is impossible to divide the patient up into neat little specialty areas to be treated without consideration of the resultant effect upon the total person – psyche and soma.

There is clearly a need for more cooperation between dental and medical sciences in research to better understand and treat the total patient, for these sciences should not and possibly cannot be separated.

Kinesthetic studies dramatically demonstrate the changes in body posture that result after mandibular-muscular spasms are eliminated. When mandibular-neuromuscular tension is removed, the mandible assumes a relaxed posture, the hyoid bone and cervical vertebrae assume a physiologic relationship, and as a result, the muscles of the upper torso, which establish the posture of the head, neck and shoulder frame begin to normalize.

The following kinesthetic studies show the changes that occurred in a four day period following the placement of a removable template to establish a physiologically balanced occlusion.

Case #96

A 39 year old clergyman was referred by a specialist, who suspected a connection between the psoriasis and the malocclusion of the teeth and the resultant respiratory and allergy problems. The patient stated that he had visited every major medical center in the USA seeking relief from the psoriasis-itching without getting relief and that he was on allergy pills around the clock for all four seasons of the year and yet he had repeated colds and spent a minimum of one week in the hospital every spring and fall with pneumonia or near pneumonia. He carried a handkerchief in his hand and was repeatedly wiping his cheeks because of the tearing from both eyes. He wore dark glasses to protect his sensitive eyes. He stood flat footed on one foot and the toes of the other. When conducting religious services he was more comfortable when standing on one foot and letting the other foot hang instead of standing on the toes.

His dental occlusion was class II with such a deep over-bite that the lower incisors contacted the gingival tissues lingual to the maxillary anterior teeth when he closed. (See pictures on page 154, Fig. 7)

Self-curing acrylic inlay-overlay fillings were placed on all mandibular and maxillary first and second molars to correct the deep overbite leaving minimal free-way space.

The following day he telephoned to inquire if he should be noticing changes so soon since the itching sensation of the legs seemed to have stopped as well as the tearing of the eyes and running of the nose.

Two days later the patient reported that he had not taken an allergy pill since the mandibular reposturization and that three parishioners had come to him the following day after services to inquire what had happened to him because his voice was so clear during his homily. He further stated that he now stood comfortably on both feet and that he could not remember ever being able to stand properly.

Three days later he reported that there had been no itching from the psoriasis and that the skin of his legs seemed to be changing, that it no longer was bleeding nor as scaly and that the psoriasis had been spreading since he was 19 years of age.

Three weeks after treatment was started he reported that he had just returned from a trip to the east coast. He was elated by the fact that he had driven two days into the morning sun without his dark glasses before he realized that he had not needed to put them on.

Gold inlay-overlays were placed on all posterior teeth after 8 months of treatment. The patient went four years before he developed his first cold. Numerous chronic problems disappeared along with the sinusitis, rhinitis, psoriasis, kyphosis, lordosis and scoliosis. He has needed only two minor occlusal adjustments since the permanent restorations replaced the acrylic treatment inlay-overlays that he wore the first two years.

Approximately two years after the bite reconstruction with gold inlay-overlays he had an unusual illness. He seemed to have caught the flu-bug. It persisted for several weeks. Finally he took a vacation going south to lay in the sun hoping complete rest would win the battle against the persistent flu-bug. After two weeks of baking in the sun it finally dawned on him that it might be his teeth. He telephoned that he was returning and wanted an appointment immediately.

The treatment consisted of removing minor premolar prematurities. The following day he returned. The flu symptoms had disappeared. It was almost ten years later that minor premolar prematurities again appeared.

Fifteen years later he reported that he was still asymptomatic.

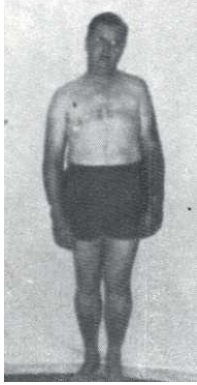

Fig. 1 AP view
(before treatment)



Fig. 2 Lateral view
(before treatment)

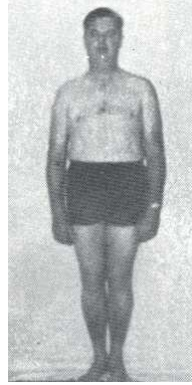


Fig. 3 AP view
(2 days later)

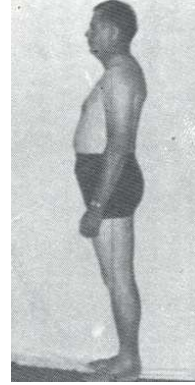


Fig. 4 Lateral view
(2 days later)

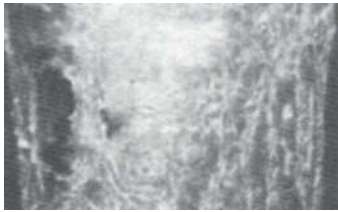

Fig. 5 Psoriasis of the legs (before treatment)

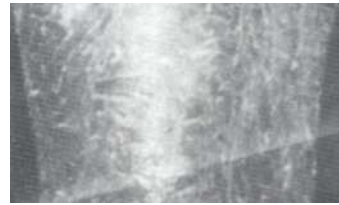


Fig. 6 Psoriasis of the legs (2 weeks after treatment)



Fig. 7 Psoriasis of the legs (6 weeks after treatment)

Case #97

A 16 year old male student presented for a routine dental examination and the parents were informed of the relationship of his posture (Fig. 9) to his maloccluded teeth. He had premature contact in the premolar area. With a minimal amount of pressure the molars came into contact. There were no alarming health problems although the routine DDS symptoms were apparent.

Occlusal amalgam fillings were placed in the mandibular second molars to provide dominant molar support "opening the bite" ½ mm. The patient did not return for any post-operative care.

After several telephone calls to his residence, the patient finally consented to follow-up radiographs when he was promised that there would be no expense involved in any of his care. (See Figs. 10-13)

This was our first case of before and after radiographs of spinal reposturization. Prior to this time the recordings were made by photographing the patients. With this case we standardized our radiographic procedures. Full spine radiographs are normally made by a single exposure for the anteroposterior views but to get optimum detail in lateral views two separate exposures are made. Note that Fig. 12 is a double exposure film and that Fig. 13 is a single exposure radiograph. We are primarily interested in recording spinal posture accurately and not in the detail in the thoracic area. We have since used single exposure on all spinal radiographs.

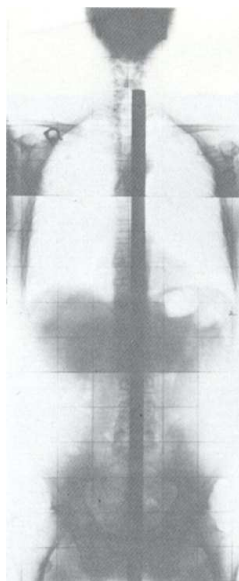


Fig. 8 Anteroposterior radiograph to depict minimal distortion utilizing a greater energy source and target – film distance.

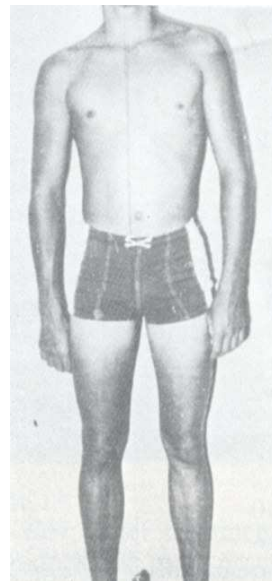


Fig. 9 Frontal View (before treatment)

The Frontal View of this 16 year old male demonstrates the body posture, especially the shoulder carriage, before treatment. Neither the parents nor the child expressed awareness of the posture problem. When the shoulder imbalance was brought to his attention and he saw himself in a full length mirror, he paled and almost fainted. Later when the full spine X-ray (Fig. 10 [below]) was taken he tried to straighten up, but the X-ray demonstrates that the Scoliosis problem could not be so easily corrected.

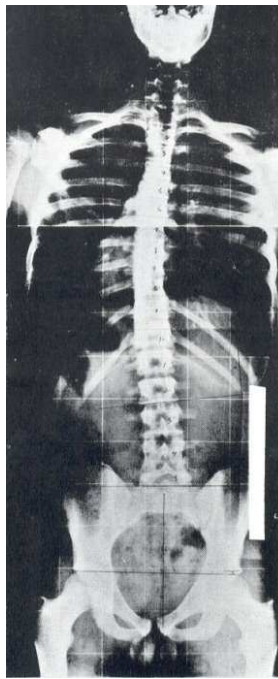

Fig. 10 Scoliosis (before treatment)

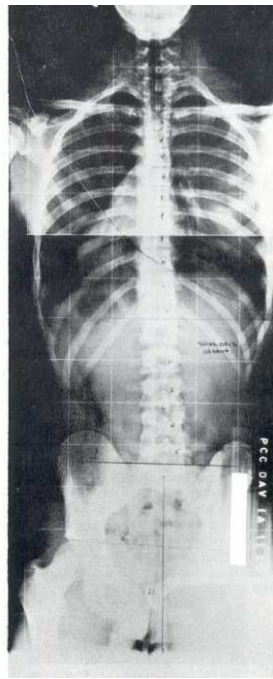


Fig. 11 Spinal posture normalization (after treatment)

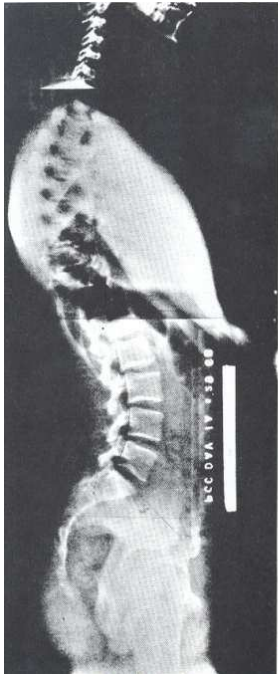

Fig. 12 Lat. View (before treatment). Note the typical double exposure used in profile X-rays to increase thoracic detail distorts the spinal picture.

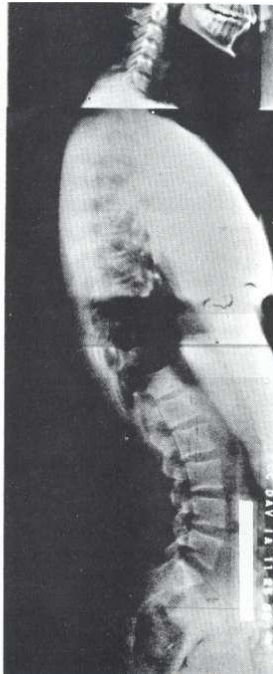

Fig. 13 Lat. View (after treatment). Single exposure X-rays more exactly record spinal posture.

Case #98

A 21 year old male chiropractic student was interested in having his occlusion corrected to normalize his posture. His deep over-bite was principally due to the fact that all his posterior teeth were in linguoversion.

Removable mandibular and maxillary expansion appliances were placed to upright all maxillary and mandibular posterior teeth. They were all in linguoversion.

Full spine radiographs confirmed an approximate 1 ½ inch reduction in the kyphosis and lordosis with a slight improvement in the scoliosis. He was one full inch taller after the initial two months of orthodontic treatment. (Figs. 14-17)

This case was chose for this presentation because we have found that it is helpful, in difficult cases, to work with a chiropractic doctor in resolving long standing spinal curvature cases. This final case (case 4) demonstrates this fact.

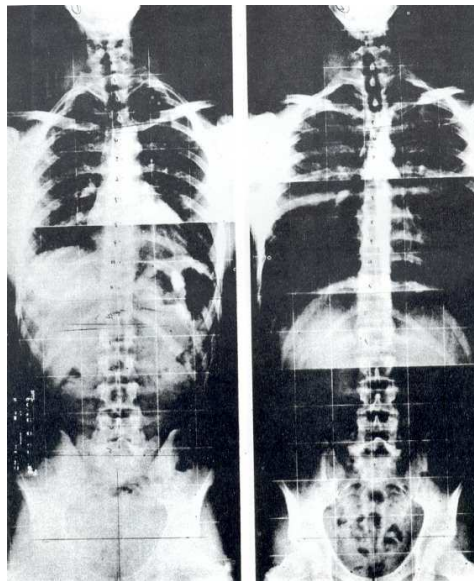


Fig. 14 AP View (before treatment)

Fig. 15 AP View (after treatment)

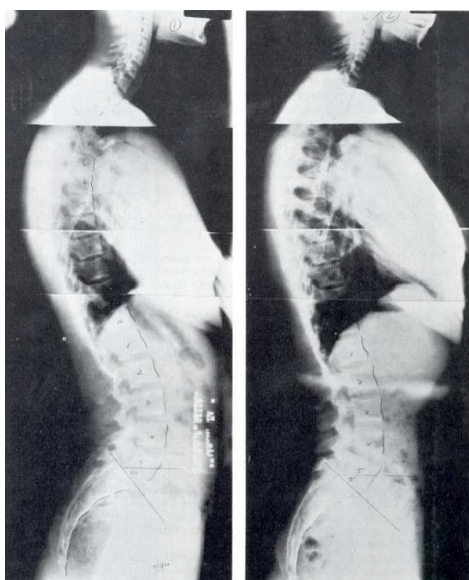


Fig. 16 Profile view shows *Kyphosis* and *Lordosis* before treatment.

Fig. 17 Profile view shows spinal posture normalization after two months of orthodontic treatment to upright posterior teeth to provide necessary molar support.

Case #99

This chronically ill and despondent housewife had contemplated suicide for she felt that she could no longer endure the pain. Severe headaches had been constant for years and would force her to bed for days at a time. Backaches were intense and she was unable to raise her arms above her shoulders. She found it extremely difficult to negotiate stairs. She was chronically ill and had worn out her welcome at several physicians offices. They told her she needed psychiatric help but she felt that her problems were real and not mentally induced. She complained of equilibrium problems, blurred vision, hearing loss, gastrointestinal problems, gynecological disturbances with severe premenstrual cramps and upsets that would put her down in bed for days plus a host of other complaints. Temporary fixed bridgework replaced missing posterior teeth to provide dominant molar support. Before she left the office the extreme tension in the cervical area that had been almost constant had subsided.

The following day she demonstrated that she was able to raise both arms above her head, negotiate steps with ease and get up and move about without losing her equilibrium. She said that she had been free of headache and backache since her occlusal corrections.

One week later she reported that she was running up and down the stairs and that her son had returned from military service and that he was dumbfounded at her activities and begged her to demonstrate over and over again how she could run up and down the stairs.

She was still free of the headache and back pain that had plagued her for years and a host of other problems. After one month she was so energetic that she had taken a job as a bridal consultant and was on her

feet all day long six days a week, up and down stairs and felt very fit all the time.

Two and one half years after treatment was initiated she admitted that she had never been back to see her medical doctor even though we had insisted that she do so. Her only additional care had been the chiropractic adjustments made immediately before each occlusal adjustment.

COMMENT: She has not had the spinal normalization that we have felt was possible mainly due to the fact that she has been enjoying her freedom from pain and illness and has not kept her appointments but has returned sporadically, when she felt like coming. To date we have been unable to get her to take the time to have the temporary acrylic bridgework replaced with permanent bridgework. (Fig. 18-21)

Radiographs of the spine before treatment:

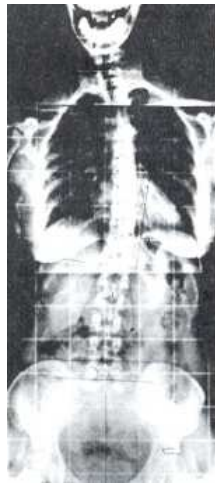


Fig. 18 AP View

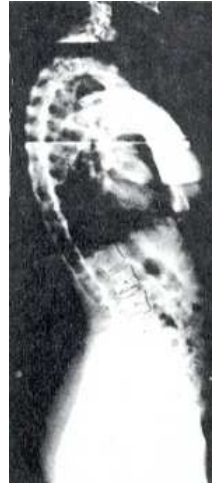

Fig. 19 Lat. View

Radiographs of the spine after treatment:

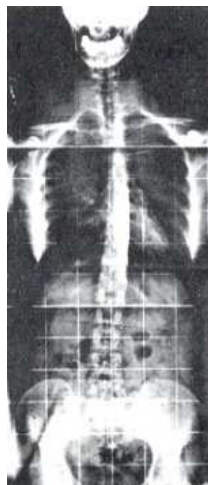


Fig. 20 AP View

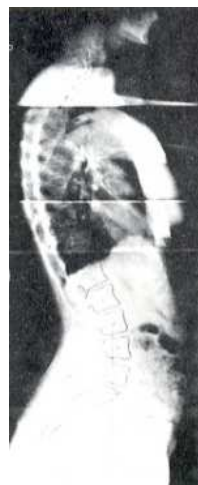

Fig. 21 Lat. View

III. Head and Neck Posture and Cephalometrics

Since we know that the sensation of position and tension of parts of the body perceived through nerve end organs in muscle, tendons, and joints determines the posture of related skeletal and vascular structures, and since we can readily demonstrate dramatic changes in posture by simple correction of malocclusion, it should be quite obvious that mandibular-neuromuscular tension problems exert considerable influence upon the total person. Observe the following roentgenographic studies of the bone structures in closest proximity to this primary source of neuromuscular imbalance.

These studies are from the files of James Ricketts, D.D.S.

Case #92

Female, age 55, office worker.

COMMENT: The patient would get up in the morning and insert her dentures. By 10:00 A.M., she would be experiencing so much head, neck and shoulder pain, she would resort to aspirin. By 11:00 A.M., her mouth would be so sore that she would have to remove the dentures and the rest of the day would live on aspirin.

Being unable to masticate and in considerable discomfort, she was naturally underweight. In addition, she was not able to sleep for more than two hours at a time, after which she would be up for varying periods of time before going back to bed.

She had worn her first set of dentures seven years.

TREATMENT: New upper and lower dentures designed to restore the lost vertical and establish physiologic function were inserted. She went home and slept fourteen hours with the dentures in her mouth.

After one week, the head and neck pains had disappeared. To date, the patient has not experienced any additional problems.

FIG. 22. Cephalometric x-ray of case #92 with old dentures. Conditions to note: luxation of the denture and mandible is evidenced by the planes of occlusion being out of balance (4-5 mm. higher on the right side).

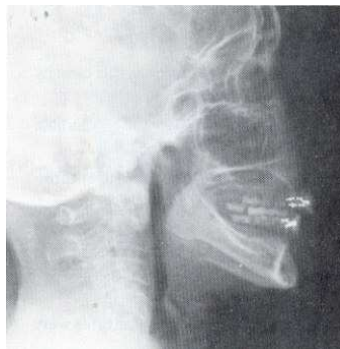


Fig. 22 Cephalometric X-ray with old dentures.

The x-ray clearly reveals the torque of the cervical vertebrae. The lateral facets starting at the second cervical are in different planes of space. The closeness of articulation at the lateral facets indicated pressure and closure of articulating space.

FIG. 23. Cephalometric x-ray of case #92 with new dentures. The lips show normal contour in conjunction with the buccinator complex. In addition, the mandibular plane angles are in a more normal relationship. The articulating space between the cervical vertebra is greater, indicating alleviation of pressure.

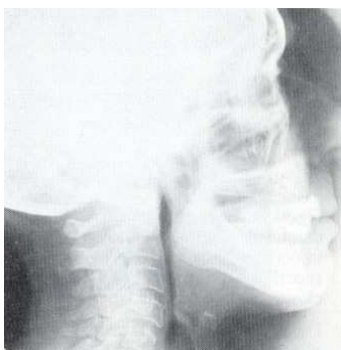

Fig. 23 Cephalometric X-ray with new dentures.

FIG. 24. Super-imposing the tracings of both the old and the new dentures, several factors are evident:

1. Anterior teeth are more in accordance with the lip length.
2. Complete cervical vertebra complex had adapted to a more normal plane of articulation.
3. The hyoid bone has moved with the cervical vertebra, but not to as great an extent.
4. Tracing only the right condyle, we can see that point D has adapted downward and forward, indicating that as we have gained posterior support, we have assisted the TMJ to achieve the articular space necessary to be nonpathologic.
5. Tip of coronoid moved forward and slightly downward. (This is very important in our girdle test and for obtaining function of the posterior fibers of the temporalis.)
6. Mandibular notch repositioned slightly forward and downward.
7. There is only a slight alteration in the morphological face height. This had remained constant except for a slight anterior positioning of the mental symphysis.

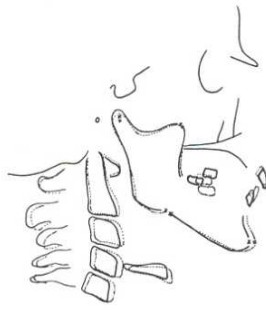


Fig. 24 Super-imposed tracings (before and after treatment)

This case offered an interesting phenomenon. While cephalometric x-rays were being taken, the patient could not get the denture to complete articulation, because of the ear rods. There was so much posterior displacement of the condyles, they were closing the external auditory meatus space as well as the TMJ space.

Case #93

Female, age 48, office worker.

COMMENT: Templates had repeatedly been suggested over a long period of time. The patient finally allowed her posterior teeth to get so sore, due to tooth interference, that they had to be removed, and she decided to go to full dentures. She had the typical syndrome: TMJ pain, neck pain, nervous tension, and a chronic cough. She went to the physician on a standing weekly appointment.

TREATMENT: Immediate dentures which restored the lost vertical and physiologic function were inserted. A week later, the cough had disappeared.

After seven months her second denture was constructed. She had somewhat more soreness and adjustments than normal, but to date, she is doing satisfactorily. The chronic problems have not recurred since the first dentures were inserted.

FIG. 25. Cephalometric x-ray in rest position.

FIG. 27. Superimposed tracings of x-rays showing alteration of structures in this case by having the patient go from rest position to closure.

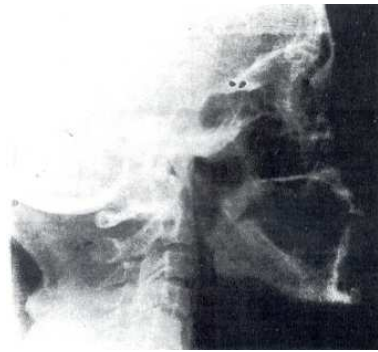


Fig. 25 Cephalometric X-ray in rest position.

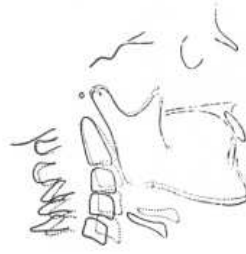


Fig. 27 Super-imposed tracings demonstrate changes in going from rest position to closure. Note the movement of the cervical vertebrae and hyoid bone.

FIG. 28. Cephalometric x-ray in closure three days after insertion of the immediate denture.

FIG. 29. Cephalometric x-ray in rest position three days after insertion of the denture.

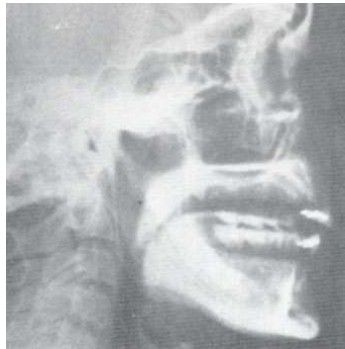

Fig. 28 In closure three days after insertion of the new dentures.

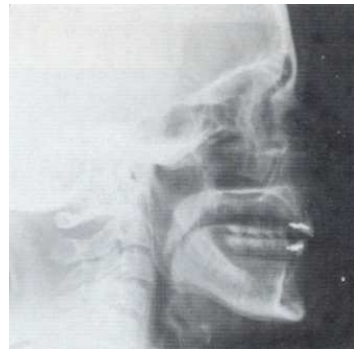

Fig. 29 In rest position three days after insertion of the new dentures.

FIG. 30. Super-imposed tracings of the x-rays three days after the insertion of the immediate dentures. Note the stability of the position of the condyle. Movement from rest position to occlusal position is now a rotational movement in the condylar area, instead of a superior and distal displacement of the head of the condyle in the movement from rest to closure, as can be noted in Fig. 6.

FIG. 31. Super-imposed tracings of the closure positions before and after dentures were placed.

FIG. 32. Super-imposed tracings of the rest position before and after dentures were placed.

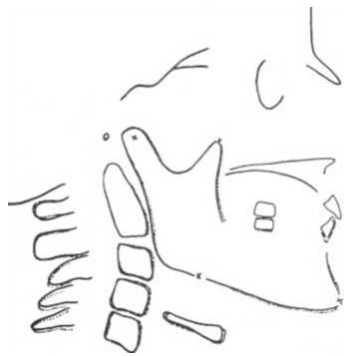

Fig. 30 Super-imposed tracings of the cephalometric X-rays taken three days after the insertion of the new dentures.

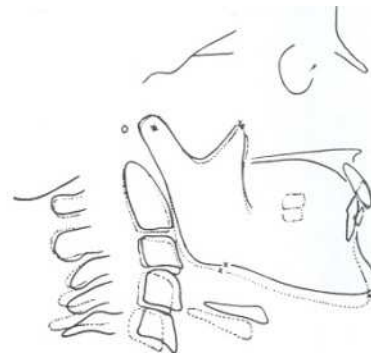


Fig. 31 Super-imposed tracings in closure, before and after dentures were placed.

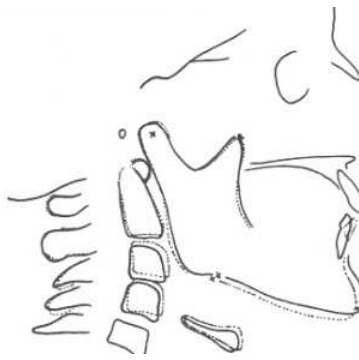


Fig. 32 Super-imposed tracings of the rest position before and after dentures were placed.

Even though rest position is the most stable position we have to start with, it is still an adaptive position dependent upon the plane of space established in articulation of the teeth (or the appliance placed in the mouth), and upon the state of tonicity of the muscles at a given period of time.

Case #94

Male, age 34, office worker.

COMMENT: The patient had the typical syndrome of headache and pains, but the most debilitating problem was the intense muscle spasms that resulted from any physical exertion, whether playing golf or only mowing the lawn.

TREATMENT: A mandibular template was inserted. The following day, the patient commented on the ease with which he could swallow. The headache, muscle spasms, and other symptoms rapidly subsided, and he played golf with no recurrence of the old problems.

FIGS. 33 & 34. Full closure (original) cephalometric x-rays and tracing.

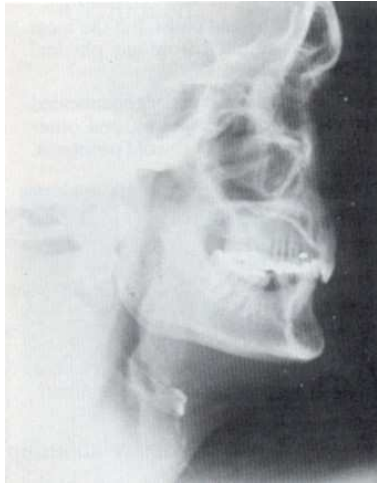


Fig. 33 Full closure cephalometric X-rays.

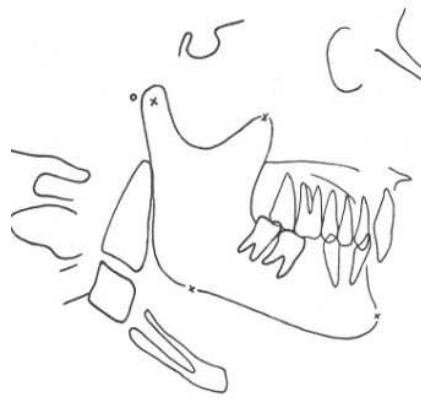


Fig. 34 Tracing in full closure before treatment.

FIGS. 35 & 36. Rest position (original) cephalometric x-rays and tracing.

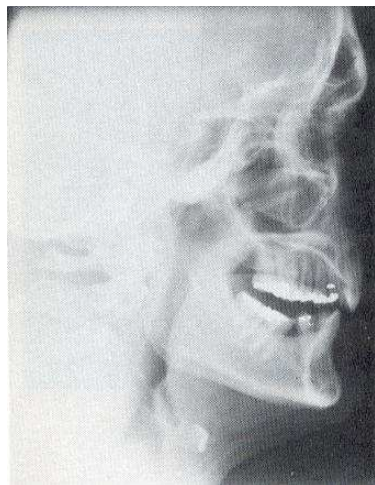

Fig. 35 Rest position cephalometric X-ray.

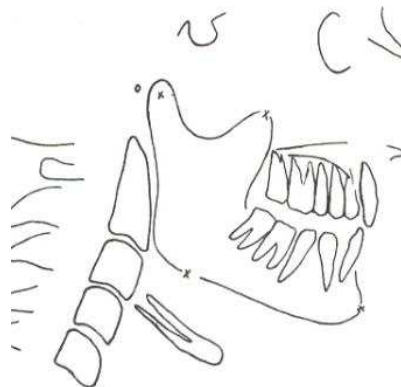

Fig. 36 Tracing of the rest position before treatment.

FIGS. 37 & 38. Full closure one month after the template was placed: cephalometric x-ray and tracing.

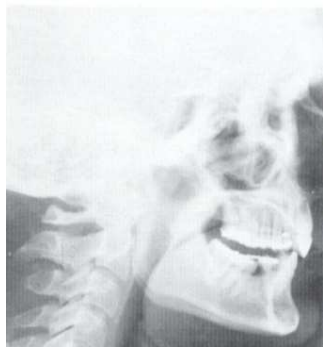

Fig. 37 Full closure X-ray, one month after template was placed.

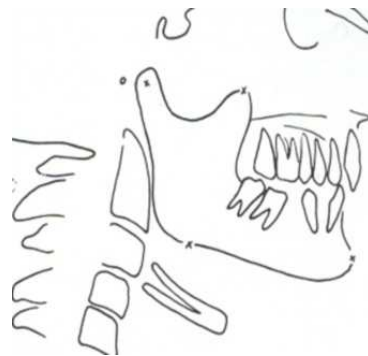


Fig. 38 Full closure tracing one month after template was placed.

FIGS. 39 & 40. Rest position one month after the template was placed; cephalometric x-ray and tracing.

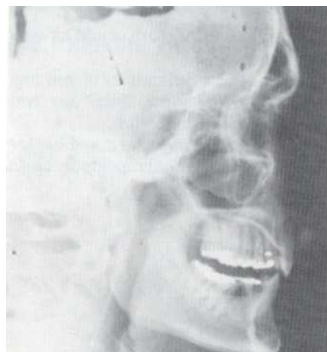

Fig. 39 Rest position X-ray one month after template was placed.

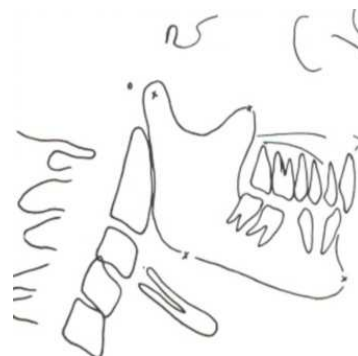

Fig. 40 Tracings of super-imposed cephalometric roentgenographs.

FIG. 41. Super-imposed tracings of original closure (black), splint one month closure (pencil) and rest position one month (red). Original rest position is between one month closure and rest.



Fig. 41 The marks indicate the relative positions of the head of the condyle, the tip of the coronoid process, the submandibular notch, and the mental process as follows:

- | | |
|--|---|
| ■ - the original closure position | □ - the original rest position |
| ● - the new closure position after one month | ○ - the new rest position after one month |

Typical alteration of structures by changing maxillo-mandibular relationship by treatment prosthesis as listed by James Ricketts are:

1. Head of condyle – forward or downward and forward.
2. Tip of coronoid process – forward or downward and forward.
3. Sub mandibular notch – downward or backward and downward.
4. Mental process – downward and backward.
5. Hyoid bone – downward and backward.
6. Cervical vertebra – backward positioning to a more normal alignment.

Case #95

A 50 year old female had been a denture wearer for 15 years. The original dentures were vulcanite. Eight years ago a new upper denture was made.

ORAL EXAMINATION: She was wearing an acrylic upper denture against a vulcanite lower denture. The lower ridge was reabsorbed. The upper denture ridge was fairly stable. There was a severe acquired prognathism and muscular imbalance. Both joints were extremely tender.

SYMPTOMS: Headaches occurred daily. Occasionally they became so severe that she would be confined to bed for two days. She could not sleep well. Occasionally she suffered “nightmares.”

However, the patient thought it was crazy to ask all these questions. She wanted a written guarantee as to the success of dentures, if new ones were constructed. She was uncooperative and reluctant to discuss the symptomatology of her case.

RESULTS: The patient volunteered that it was worth going through all of this primary procedure to get rid of her headaches. This was the first time that she was free of headaches since she could remember. She was resting well, slept better and was easier to live with.

CEPHALOMETRIC X-RAYS: Tracing of the before (Fig. 1) and after two months (Fig. 2) Cephalometric roentgenograms show suspension in the fossae, reposturization of the hyoid and cervical vertebrae and that the vertical in the anterior tooth area had been restored 17 ½ mm.

The patient was told that in all probability the upper posterior teeth would have to be reset in a few months, for which service she would be charged.

In the process of constructing these new dentures, it was difficult to obtain any maxillomandibular relativity since she did not close into the same “bite” any two consecutive times. There had been a complete loss of any proprioception.

When the new dentures were first inserted she tended to protrude the mandible for the first week. Finally after more than a month she stabilized; she would repeatedly close into the same maxillo-mandibular relationship.

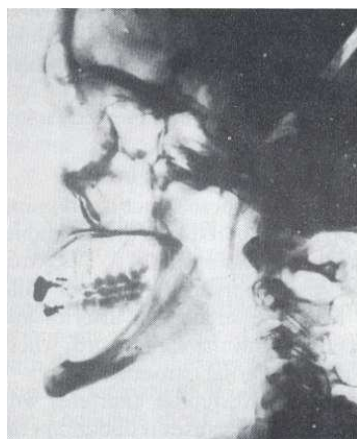


Fig. 42 Before treatment

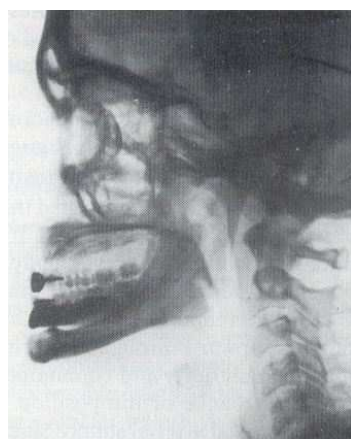


Fig. 43 After treatment

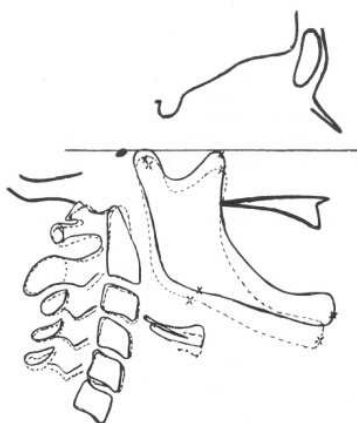


Fig. 44 Solid line is before treatment. Broken line is after treatment.

Examination of these cephalometric studies leaves little doubt of the changes in position of the condyles, hyoid bone, and cervical vertebrae which take place as a result of disturbed mandibular musculature. The malposition of the cervical vertebrae has a number of implications, only a few of which will be suggested.

A. Disturbance of Vascular Supply as a Result of Malposition of the Cervical Vertebrae

Brescia²⁴ has demonstrated that disturbance of these structures disrupts vascular supply to the cranium. It must be remembered that the ascending internal carotid artery eventually forms the arterial circle of Willis, from which all arteries supplying the brain arise. Also supplying the circle of Willis are the vertebral arteries, which arise from the

subclavian arteries and progress upward through the frenum magnum with the spinal cord, where they run anteriorly and communicate with the internal carotid.

Disturbance of the position of the cervical vertebrae interferes with proper cranial arterial supply, since this malposition causes reduction in the proper vertebral arterial flow. This results in anoxia to the brain. Varying degrees of headache* are the chief disturbing result.

Smith has demonstrated by controlled studies²⁵ that blood supply to the brain and extremities can double or even quadruple when the vertical is properly increased.

B. Effects upon the Cranial and Cervical Neural Pathways

Changes in the vertebral column at any point in its length are capable of working mutations upon the dura mater, arachnoid, and pia mater layers of the spinal cord.

Posterior dissection of the viscera of the neck will exhibit a close relationship of the sympathetic and parasympathetic neural supply and the muscular and skeletal structures in the neck. A change in vertebral position is quite capable of inducing pathologic stimulation of these neural structures, which would result in a number of more or less severe dysfunctions, not only in the head, but also in the rest of the body, since the cranial outflow, notably the vagus, must pass in intimate relationship to this structures. Pressure on the symphysis plexus would affect the nerves to the pituitary gland, for instance.

Sinclair²⁶ observed in fluoroscopic series the skull rocking on the atlas vertebra and the cervical vertebrae swaying during mastication. When one considers the movement of the cervical vertebrae that occurs during mastication, the possibility of damage by the malpositioned vertebrae becomes alarming. Questioning a person who is troubled by a temporomandibular joint problem will invariably reveal aching and tiredness at the nape of the neck and the base of the skull.

In short, this malpositioning of the cervical vertebrae, the hyoid bone, and all the vital structures in this area, due to improper mandibular muscle tonus, have extremely important implications as a source of stress in the patient.

C. Pathology of the Temporomandibular Joint

Often the patient does not suspect disorder within the joint until considerable pathological progress has been made. Frequently, until actual pain develops, he is not aware that anything is amiss, and it is possible that by the time pain begins, considerable damage has occurred. It is at the stage when symptoms are first noted that the greatest degree of

* Ventilating the lungs by taking several deep breaths increases the oxygen content in the blood, and often relieves the headache. Logically, relief is more easily effected in the early stages of the onset of headache.

success can be achieved with the proper therapy. Since the early symptomatology usually goes unnoticed by the patient, it becomes the dentist's responsibility to discover disorder. The joints should be examined during every six month visit.

In this regard, the significance of minute degenerative changes of the tissues of the masticatory organs has received insufficient emphasis. One of the consequences of the violation or misapplication of the laws of biomechanics may be the actual degeneration and destruction of tissue. The course of such degeneration and destruction can be traced from minor beginnings to almost total collapse.

1. MICROTRAUMATA AND MACROTRAUMATA IN THE TEMPOROMANDIBULAR JOINT. Repeated condylar microtraumata within the joint are a contributing factor to temporomandibular joint dysarthrosis, according to Shore.²⁷ These repeated condylar microtraumata cause interference with the nutrient supply, which in turn interferes with the lubrication of the articular surfaces of the joint and with its nutrition. The deeper curves of spee and deep over-bites are most apt to cause problems.

Temporomandibular joint malarthrosis produces, in varying degrees, compression, stretching, tearing, and degeneration of the joint tissues, which are among the least regenerative in the human body. Also, such tissue changes within the joint are rarely revealed except by surgery.

2. CLINICAL SYMPTOMS WITHIN THE JOINT. The clinical manifestations of temporomandibular joint malarthrosis, in the order in which they usually occur, include: clicking, crackling noises, crepitation, tenderness, and pain in and around the joint. The neuromuscular manifestations also include limited mandibular movements with or without pain, difficulty in opening the jaws in the morning, mandibular lock in certain positions on opening, compensation of the contralateral joint by hypermobility, subluxation, irregular mandibular opening and closing movements, condylar hypermobility, and the infrequent symptom of swelling in the preauricular area. Inflammation occurs only in extremely complicated cases.

3. ROENTGEN INTERPRETATION OF THE TEMPOROMANDIBULAR JOINT. Reontgenograms are of assistance in the diagnosis of certain temporomandibular joint relationships, especially those concerned with positional relations of the condylar heads to the mandibular fossae and the articular tubercles. Ricketts and Morrey feel that "many laminagraphic studies are necessary, particularly on adults with degenerative joint diseases."²⁸ Morphologic changes such as dislocations, displacement of the mandibular condyle due to fracture, increased density of the condylar head following pathologic changes, or an attenuated condyle and narrow condylar neck can be identified by means of proper techniques.²⁹

In one study, Norgaard,³⁰ using his anthrographic technique, roentgenographed a large number of patients who complained of temporomandibular joint symptoms. He injected Perabrodil first into the lower joint cavity and then into the upper joint cavity, making it possible

to visualize these changes and their relations to the meniscus, the glenoid fossa, and the condyle. Displacement of the fluid by movements of the condyle revealed further information concerning the joint. Thus, it was possible to detect a perforated meniscus, adhesions between the various structures within the joint, obliteration of portions of the joint cavities, and other pathologic conditions.

Transcranial x-ray views should be considered minimal. Lamina-graphs will be more revealing. There is no substitute for good x-ray pictures and intelligent interpretation of them. However a caution against depending entirely on roentgenograms is in order here, since interpretation of them can be very misleading. The mandibular fossa, for example, can appear shallow or wide, without such a condition actually existing. Degenerative changes in the articular capsule or the articular disc are not visible in the roentgenogram of the joint. In postmortem examinations of the temporomandibular joints, pathology and even complete destruction of articular discs has been found in persons who exhibited no signs or symptoms of joint disturbance before death. Also, the greatest portion of the dimensional area of the joint remains relatively obscure in the roentgen film. Lateral views of the joint do not offer a true three-dimensional picture of the mandibular fossae, the articular tubercles, or the mandibular condyles. For such reasons, one should hesitate to make a diagnosis of changes occurring in the joint based on roentgenologic interpretations only.

D. Summary

In summarizing the pathology of the joint, it becomes clear that: pathologic occlusion, in addition to influencing the musculature of mastication, can cause, either directly or through the musculature, a malarthrosis of the temporomandibular joint. This malarthrosis can range from microtraumata in the early stages to considerable macrotraumata. If this ends in acute degeneration, we have an additional localized source of distress. This distress, in turn has considerable implications for the rest of the body.

IV. Growth Arrest

Sarnat and Ricketts remind us that

...the temporomandibular joint provides growth for the lower jaw at the chondrogenic zone in the condylar head. Either an incomplete differentiation or a pathologic destruction of the cartilaginous cells, or a hyperphasia of cells in this area will therefore influence the ultimate shape of this articulation and other facial form...

...arrest of growth can occur as a result of rheumatoid arthritis, extension from septic infection, or from direct trauma....Early arrest of growth of the condyle not only affects mandibular growth, but also seems to

affect the growth of the rest of the face as well. This is undoubtedly due to muscular adaptation and compensation for the lack of growth.³²

During the late 1970s and the 1980s greater interest has been shown in joint problems and Ravins^{31 32} contends that too much emphasis has been placed on the condylar growth. European functional orthotic orthopedic appliances and the dramatic changes in facial development and arch form demonstrates that in the past we have been too conservative in our possibility thinking and much too quick to extract teeth and collapsing arches and the premaxillae. This orthodontic approach has caused TMJ and consequent health sequelae. It has led to considerable legal entanglements and rethinking in orthodontic circles.

Brodie has this to say about growth as it relates to the temporomandibular joint:

1. Studies on the growth of the human face have shown that in order that development proceed in an orderly fashion, a prolific growth at the head of the condyle is absolutely necessary. Growth at this site is at a higher rate and continues for a longer time than at any other part of the mandible.

2. Condylar growth may be partly or totally corrected or inhibited congenitally or as a result of infections of the middle ear, arthritis, trauma (accidental or surgical), or by radiation therapy.³³

Some interesting research has been done on changes in adult face height. A Roentgen cephalometric study by Tallgren³⁴ on changes in the adult face height due to aging, wear and loss of teeth, and prosthetic treatment demonstrated that all growth in the head does not cease when the person is "fully grown." On the contrary, a significant increase in body morphologic face height and rest face height was found from the age group 20-29 up to the oldest age group 50-81 years.

Wunche³⁵ observed continued increase in the morphologic face height right up to the age of 41-45 in men, with no reduction of face height until after 60. In women, the face height reduction was apparent at age 45. Buchi,³⁶ in a control period of nine years, found a significant increase in the morphologic face height up to the age of 46. Continued growth was observed up to the age of 56-64 (3 ½ mm. or around 3%). No decrease in face height was manifest until after the age of 70.

The relationship between the average morphologic face height and the average rest face height remains constant throughout life if the dentition does not undergo destructive changes. Sicher,³⁷ Thompson and Brodie,³⁸ and others found that the inter-occlusal space remained constant throughout life if no malocclusion existed and that the rest position was dependent on the muscle tonicity, but that severe illness, extreme muscle trismus, and generally diminished muscle tonus could occasion changes in the rest position.

Tallgren³⁹ also found that inter-occlusal clearance increased with the degree of abrasion and that morphologic face height was greatly reduced through abrasion. Long term denture wearers showed the sharpest reduction in morphologic face height, averaging 13 mm., about 7 mm. greater than the abrasion group. Even short term denture wearers showed a marked reduction in morphologic face height. – 2 mm. the first six months and .7 mm. the second six months, while the inter-occlusal clearance increased accordingly.

The author contends that a corresponding functional adaptation in the neuro-muscular system accompanies the skeletal growth of the morphologic face height. The inter-occlusal space normally remains constant, but when malocclusion, abrasion, or resorption under dentures upsets the neuromuscular balance, the interocclusal space increases, morphologic face height decreases, and a condition of distress develops.

V. Comment on the Dental Origin of Distress

The main avenue of distress of dental origin is the malfunction of the mandibular musculature that routinely accompanies dental malocclusion. This will not only cause distress of itself, but will result in the displacement of cervical vertebrae and in a repositioning of the spine, pelvis, shoulder girdle, and head. All of the skeletal structures are affected, and the temporomandibular joint is only one aspect of the traumatization and distress. Too much emphasis has been placed on the “TMJ” as the problem when it is in fact one of many symptom areas.

Dysarthrosis of the temporomandibular joint then becomes an additional distress factor. This dysfunction of the stomatognathical structures is capable of initiating all the mechanisms of the General Adaptation Syndrome. Because such muscular dysfunction is constant, it may cause a derailment of the body’s adaptive processes, or may act as a conditioning factor for other distressful elements.

It is the writer’s opinion that once the constant dental distress is removed, the body is more able to cope with other stressors through normal, physiologic adaptation. Bodily energies can then be devoted to healing when before they were needed for survival. If these stressors have not already become self-sustaining, the patient’s disorders disappear or are mitigated. This will become more apparent with the study of individual areas of complaint in Part II.

References

1. Thompson, J.R.: The rest position of the mandible and its significance to dental science. *J.A.D.A.*, 33: 151-180, 1946.
2. Sinclair, W.M.: The physiology of the temporomandibular joint. *Amer. Equilibration Soc. Compendium*, 6: 37-63, 1962.

3. Boucher, L.J.: Discussion of the physiology of the temporomandibular joint by W.M. Sinclair. *Amer. Equil. Soc. Compendium*, 6: 64-65, 1962.
4. Boucher, Scotter & Charlebois: The use of cone fluorography in dentistry. *The Greater Milwaukee Dental Bulletin*, 30, 1964.
5. Guzey, C.M.: *The Quadrant Theorem*, distributed by Doctors Dental Service, Chicago, Illinois, 1980.
6. Ricketts, R.M.: *The Temporomandibular Joint*, 2nd ed. B.G. Sarnat, ed. Thomas, Springfield, Illinois, 1964.
7. Storberg, C.G.: Physiologic dentistry. *J. Nat. Assoc. Seventh Day Adventist Dentists*, 5: 4, 1963.
8. *Ibid.*
9. Thompson, J.R.: *The Temporomandibular Joint*. B.G. Sarnat, ed. Thomas, Springfield, Illinois, 1964.
10. Thompson, J.R.: Oral and environmental factors as etiological factors in malocclusion of the teeth. *Amer. J. Ortho.*, 35: 33, 1948.
11. Storberg, *op. cit.*
12. Thompson & Brodie: Factors in the position of the mandible. *J.A.D.A.*, 29: 924-941, 1942.
13. Thompson, The rest position, *op. cit.*
14. Storberg, *op. cit.*
15. Brodie, A.G.: *The Temporomandibular Joint*, 2nd ed. B.G. Sarnat, ed. Thomas, Springfield, Illinois, 1964.
16. Thompson, The rest position, *op. cit.*
17. Thompson, *The Temporomandibular Joint*, *op. cit.*
18. Storberg, *op. cit.*
19. Farrar, W.B. & McCarty, W.L., Jr.: The TMJ dilemma. *Alabama Dent. Assoc.*, 63: 19, Winter 1979.
20. Lewis, T.: *Pain*. Macmillan, New York, 1942.
21. Thonner, E.D.: Aural symptoms in relation to the temporomandibular joint. *Acta. Odont. Scandinav.*, 10: 180, 1953.
22. Freese, A.S. & Sherman, P.: *Management of Temporomandibular Joint Problems*. Mosby, St. Louis, 1962.
23. Travell, J. & Bigelow, N.H.: Role of somatic trigger areas in the patterns of hysteria. *Psychosom. Med.*, 9: 353-363, 1947.
24. Brescia, N.J.: Address to the American Academy of Physiologic Dentistry, June 24, 1964.

25. Smith, S.D.: *Atlas of Temporomandibular Orthopedics*. Phil. Col. Of Osteopathic Med., 1981.
26. Sinclair, *op. cit.*
27. Shore, N.A.: *Occlusal Equilibration and Temporomandibular Joint Dysfunction*. J.B. Lippincott, Philadelphia, 1959.
28. Ricketts & Morrey: Present status of laminagraphy as related to dentistry. *J.A.D.A.*, July, 1962.
29. Personal communication of H.A. Held and H.H. Shapiro, M.D.
30. Norgaard, F.: Arthrography of mandibular joint. *Acta. Radiol.* 25: 679, 1944.
31. Ricketts, *The Temporomandibular Joint*, *op cit.*
32. Brodie, *op. cit.*
33. Tallgren, A.: Changes in adult face height due to aging, wear and loss of teeth and prosthetic treatment. *Suomalaisen Kirjallisuuden Kirjapaino oy Helsinki*, April, 1957.
34. Wunche, H.W.: Altersveränderungen Metrischer Merkmale in der Kindheit und beim Erwachsenen, sowie ihre Beziehung zum Sozialen Milieu und zum Habitus. *Zschr. Morph. Anthropol.*, 45: 368, 1953.
35. Buchi, E.C. Änderungen der Körperform beim Erwachsenen Menschen. *Anthropologische Forschungen Anthrop. Gesd.*, Heft. 1, Horn-Weim, 1950.
36. Sicher, J.: Positions and movements of the mandible. *J.A.D.A.* 48: 620, 1954.
37. Thompson & Brodie: Factors in the position of the mandible. *J.A.D.A.* 29: 925, 1942.
38. Tallgren, *op. cit.*
39. Leeds, A.B. & May, W.B.: Arthritic symptoms related to position and function of mandible. *Basal Facts*, 2: 66, 1977.
40. Fonder, A.C.: The role of the dental physician. Lecture series at Universidade de Sao Paulo, Faculdade de odontologia, Sao Paulo, Brazil, Nov. 1961.
41. Fonder, A.C.: Medico-dental problems. Lecture at Institut Universitaire de Medicine Dentaire, Geneva, Switzerland, Oct. 1963.
42. Fonder, A.C., Alter, J.L., Allemand, L.E. & Monks, W.W.: Malocclusion as it relates to general health. *Illinois Dent. J.* 34: 292, 1965.

43. Fonder, A.C.: Dental distress, respiratory and posture problems. American Dental Association Meeting, Houston, Texas, October, 1973.
44. Khoroshilkina, F. Ya., Malygin, Yu. M., Nesulkovsky, Ya. A. & Tsyplenkov, V.G.: Sinusobronchial pneumopathy and disturbances of posture in patients with saggital anomalies of bite. *Stomatologia* 49: 65, July-Aug., 1970.
45. Fonder, A.C.: Dental malocclusion and spinal posture. Essay, Amer. Dent. Assoc. Ann. Meet., Las Vegas, Nov. 1971.
46. Fonder, A.C.: *The Dental Physician*. Blacksburg, Va., University Publications.
47. Whatmore, G.B. & Kohli, D.R.: *The Physiopathology and Treatment of Functional Disorders*. New York – London, Grune and Stratton, 1974.
48. Whatmore, G.B. & Kohli, D.R.: The concept, physiopathology. In: *The Physiopathology of Stressful Disorders*, Edited by A.C. Fonder, in press for 1980.
49. Uhlemeyer, H.A.: Combined dental and E.N.T. approach to T.M.J. dysfunction. *Basal Facts*, 2: 60, 1977.
50. Diamond, J. Personal communication, 1977.
51. Smith, S.D.: Chronic illness profiles. *Basal Facts*, 3: 78, 1978.
52. Berkman, E.H.: The Troublesome TMJ: The fascia colli in Gray's Anatomy. *A.C.A.J. Chir.* 5: 41, June, 1971.
53. Brescia, N.J.: Head and neck anatomy. Lectures to the A.A. of Physiologic Dent., June 1964.
54. von Holst, E. & Mittelstaedt, H.: *Naturwissenschaften* 37: 464, 1950.
55. Goodheart, G.J.: *Applied Kinesiology Systems*, D.C. (Private publication: 542 Michigan Building), Detroit, 13th ed., 1977.
56. Walther, D.S.: *Applied Kinesiology Systems*, D.C. (Private publication), Pueblo, Colo., 1976.
57. Eversaul, G.A.: *Dental Kinesiology*. Las Vegas, Box 19476, 1977.
58. Tinbergen, N.: Ethology and stress diseases (Nobel lecture, Sweden, Dec. 12, 1973) *Am. Assoc. for Advancement of Science* 185: 20, 1974.
59. Barlow, W. *The Alexander Principle*. Gollancz, London, 1973.
60. Dewey, J.: *The Use of Self*. Chaterson, London 1932.
61. Huxley, A.: *Ends and Means*. Chatto and Windus, London, 1937.
62. Coghill, G.E.: Appreciation: The educational methods of F. Mathias Alexander. In: *The Universal Concept of Living*. Dutton, New York, 1941.

63. Dart, R.A.: *S. Afr. Med. J.* 21: 74, 1947: An anatomist's tribute to F.M. Alexander, Sheildrake Press, London, 1970.
64. Sherrington, C.S.: *The Endeavor of Jean Fernel*. Cambridge Univ. Press, London, 1951.

Suggested additional reading must include the latest works of:

Bell, W.E.
Farrar, W.B., and McCarty, W.L., Jr.
Frumker, S.
Jankelson, Bernard and Associates
Mongi, Mikhail and Rosen
Roth, D.R.
Saadia, A.M., and Associates
Smith, S.D.
Smith, G.H.
Stack, B.
Weinberg, L.A.

The American Equilibration Compendium, Volumes 15 and 16 especially

Currently there is so much being published on "TMJ" and the handling of muscle, jaw and joint problems that this list is grossly inadequate.